

PHILIPS

Ultrasound

Clinical case study

The eL18-4 PureWave linear array with MicroFlow Imaging (MFI) in diagnosis of thyroid cancer and lymph node metastasis both pre- and post-op

eL18-4 PureWave linear array transducer

Category

Thyroid, Head and Neck, and Lymph Node Assessment

Authors

Lynwood W. Hammers, DO
Consultant Radiologist

Hammers Healthcare Imaging, LLC
New Haven, CT

Overview

Diagnostic ultrasound is the standard for the evaluation and biopsy of thyroid cancer and metastatic lymph nodes.¹ Ultrasound is the most definitive modality when frequent follow-up exams are required for possible reoccurrence.

Patient history

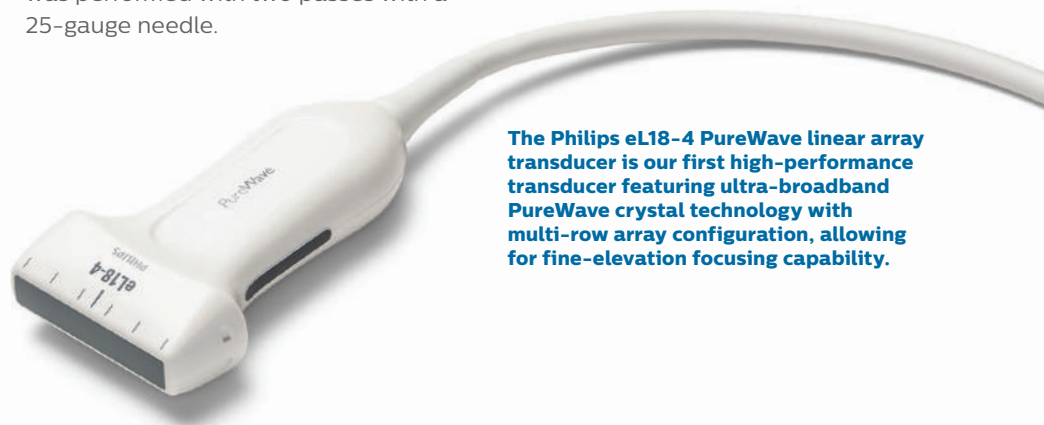The patient was a 68-year-old male with prior biopsy of 3.9 cm heterogeneous right thyroid cancer with well marginated borders without calcification. The cancer was biopsied in 2016. By the new ACR criteria this would have been a TIRADS 4 nodule. A complete thyroidectomy was performed with no metastasis to the central or lateral neck. The patient now presented for initial post-op evaluation with a negative thyroglobulin level.

Protocol

Central and lateral neck lymph nodes were evaluated with the eL18-4 transducer and utilization of MFI vascular assessment. Linear and transverse imaging was performed of the central and lateral neck to evaluate for residual cancer or metastatic lymph nodes. FNA was performed with two passes with a 25-gauge needle.

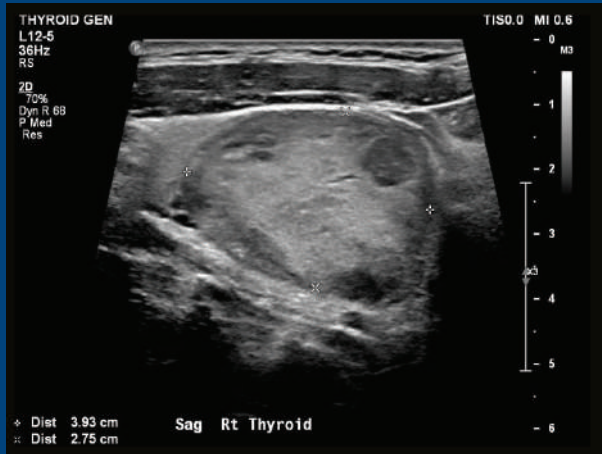
Findings

Multiple classic post-op granulomas were visualized in the right and left level 6 regions, as seen in the middle image. On the right image was a left level 6 hypoechoic mass that was well marginated without calcium. However, there was a small amount of fluid. The differential included post-op scarring because of the normal thyroglobulin level and the presence of the multiple granuloma (as seen in the middle image). The differential also included residual thyroid versus metastatic cancer to the opposite side of the original cancer. MFI revealed vascular flow with reinforcement of the need to biopsy. Cytopathology revealed metastatic LL6 lymph node.

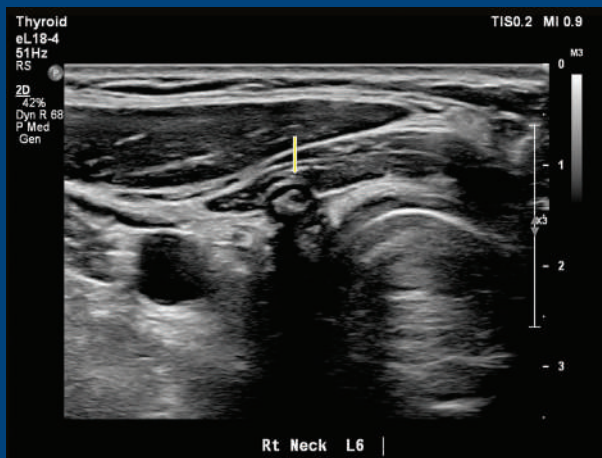


The Philips eL18-4 PureWave linear array transducer is our first high-performance transducer featuring ultra-broadband PureWave crystal technology with multi-row array configuration, allowing for fine-elevation focusing capability.

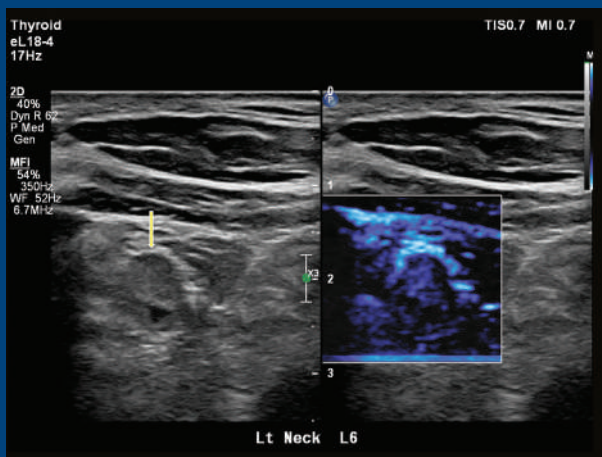
Clinical case study: The eL18-4 PureWave linear array with MicroFlow Imaging (MFI) in diagnosis of thyroid cancer and lymph node metastasis both pre- and post-op



Original thyroid cancer.



Post-op imaging using eL18-4 transducer.



Post-op imaging using eL18-4 transducer with MFI.

Conclusion

The possibility of metastatic thyroid cancer post complete thyroidectomy with a normal thyroglobulin level is rare but does occur. The patient had definitive post-op scarring with granuloma, raising suspicion that the LL6 mass was another area of scarring. MFI revealed definitive vascular flow, raising strong suspicion for cancer, which led to the correct procedure – biopsy – which revealed cancer.

The superficial imaging and vascular MFI capabilities of the eL18-4 makes it a superb transducer for thyroid and head and neck imaging. In the literature, vascular imaging of the thyroid nodules and lymph nodes has not proven to be of great value in evaluation of primary or metastatic thyroid cancer.

This case clearly demonstrates the increased sensitivity and therefore value of the eL18-4 with MFI in assessment of thyroid cancer metastasis.

Reference

1 Tessler FN, MD, CM; Hammers LW, DO; et al. ACR Thyroid Imaging, Reporting and Data System (TI-RADS): White Paper of the ACR TI-RADS Committee. JACR 2017.

Results from case studies are not predictive of results in other cases. Results in other cases may vary.